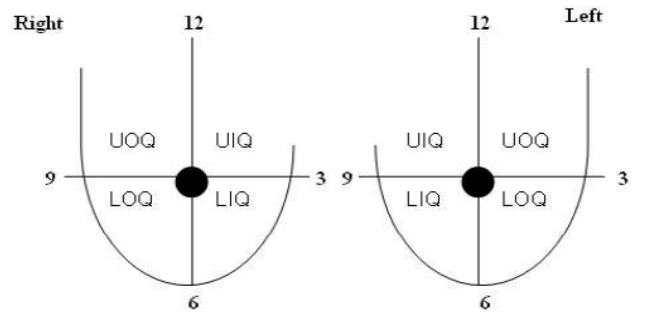


RADIOGRAPHER FINDINGS :-

Please note any:

Scar	
Mole	
Lump	
Nipple changes	
Skin Folds	



Projection		kVp	mAs	Thickness	Dose	No of images	PGMI score
Right	CC						
	MLO						
Left	CC						
	MLO						
Additional views							
Repeat projections							

(Signature of Radiographer)